

Государственное бюджетное учреждение
«Профессиональная образовательная организация
«Астраханский базовый медицинский колледж»

Предмет: «Английский язык»

Тема: «Teeth»

Специальность «Стоматология ортопедическая»



Преподаватель: Воронцова С.Ф.

Астрахань – 2017г.

План

- 1. Анатомическое строение зуба.**
- 2. Заболевание зубов.**
- 3. Профилактика заболеваний.**
- 4. Стоматологический инструментарий.**



words to memorize:

adult teeth — коренные зубы

baby teeth — молочные зубы

back teeth — задние зубы

canine — клык

central incisor — средний резец

first molar — первый коренной зуб

front teeth — передние зубы

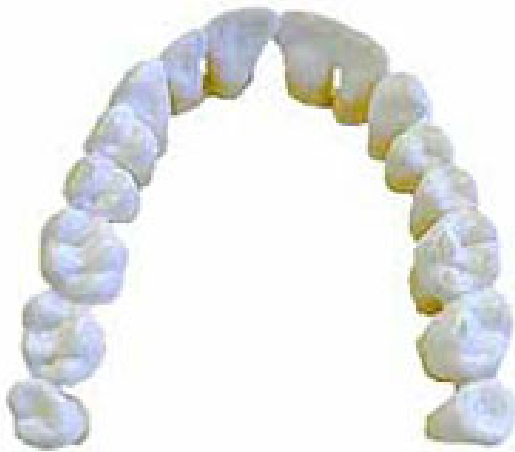lateral incisor — средние резцы

wisdom teeth — зубы мудрости

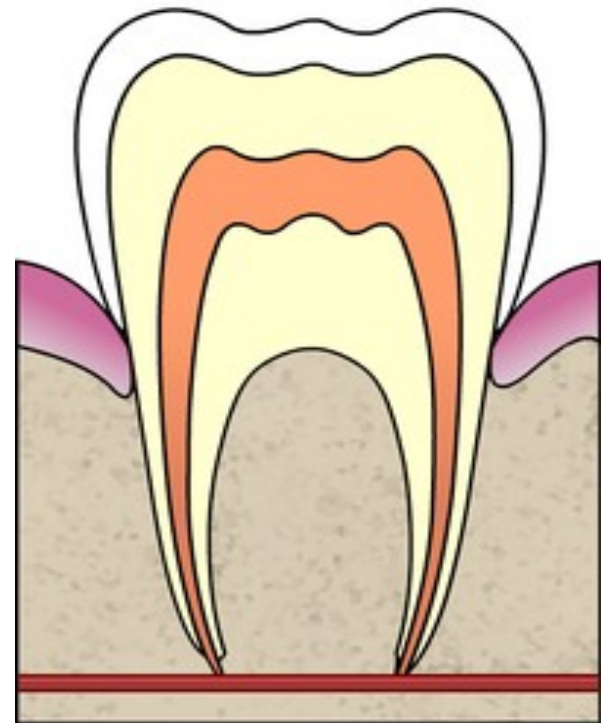
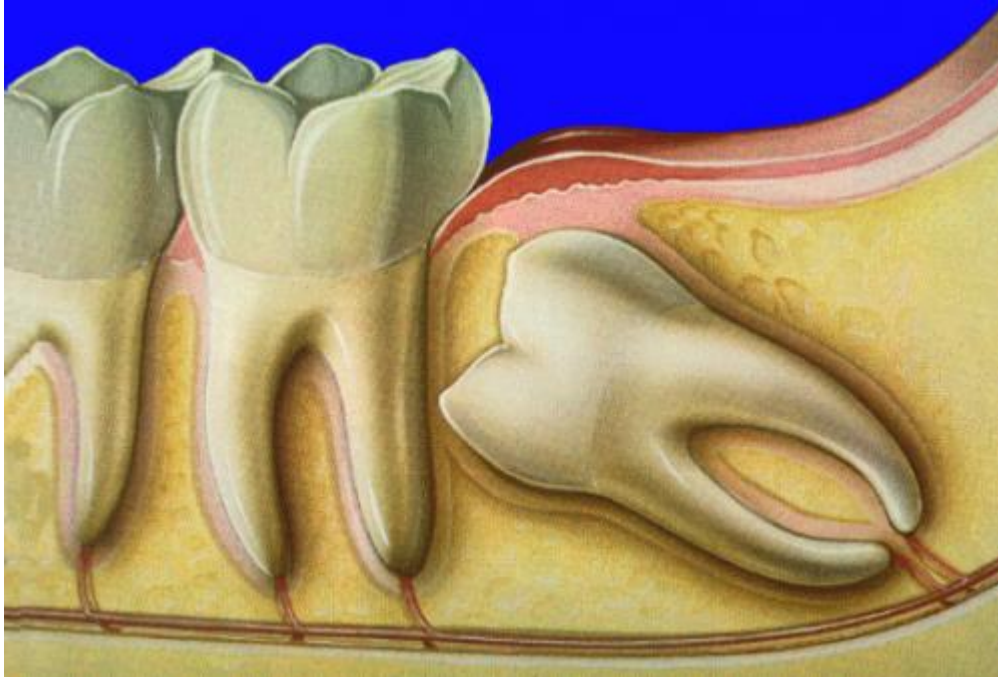oral hygiene — гигиена ротовой полости

bleeding gums — кровоточащие десна

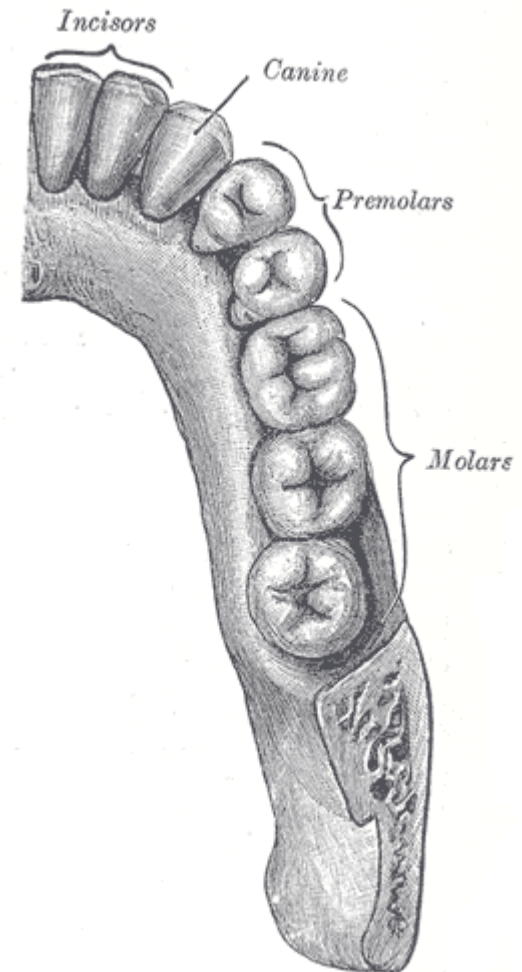
- The teeth are in the upper and lower jaws. The teeth are not bony structures. Man has two sets of teeth only. The first set begins to develop when the human body is three or six month old.



- They are located in the cells of the jaws and communicating with their connections, which are a kind of shock absorbers during chewing. In 32 adult teeth: two incisors, one canine, two premolars and three molars on each side of each jaw.



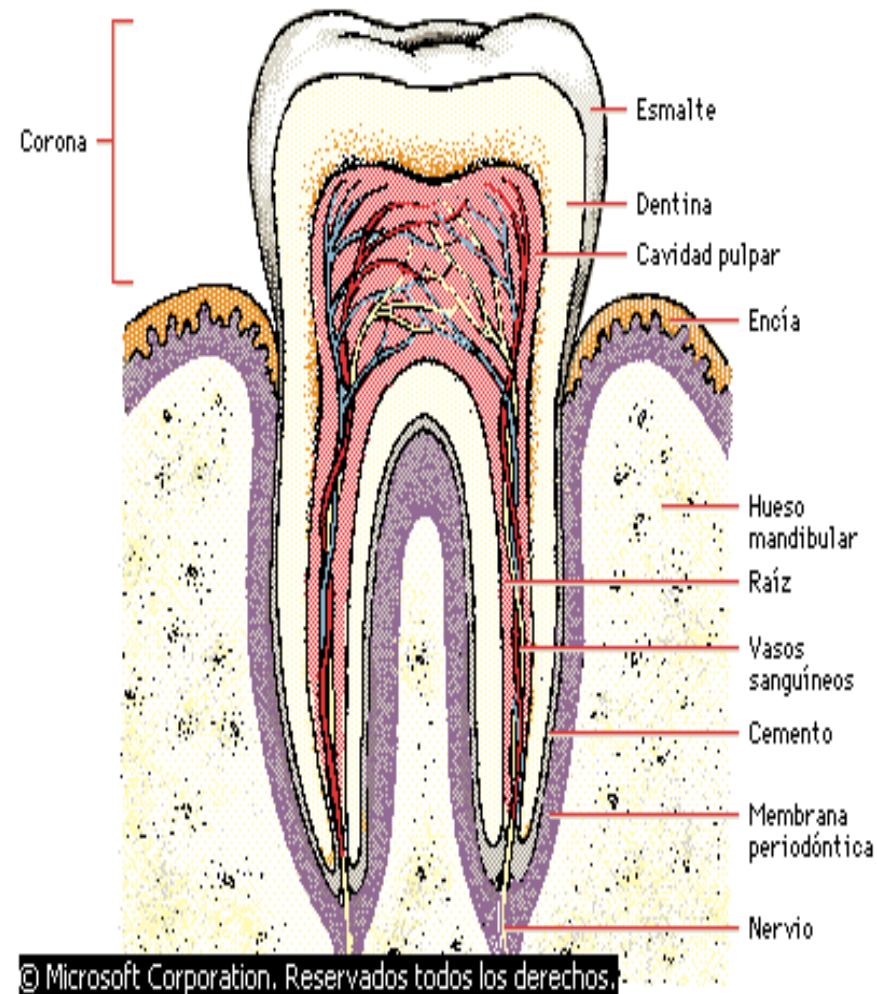
- Cutters have cutting edge to nibble food, canines tear food and lowercase molars crush and grind it. Due to the increased surface grinding food digestive enzymes that facilitate digestion.



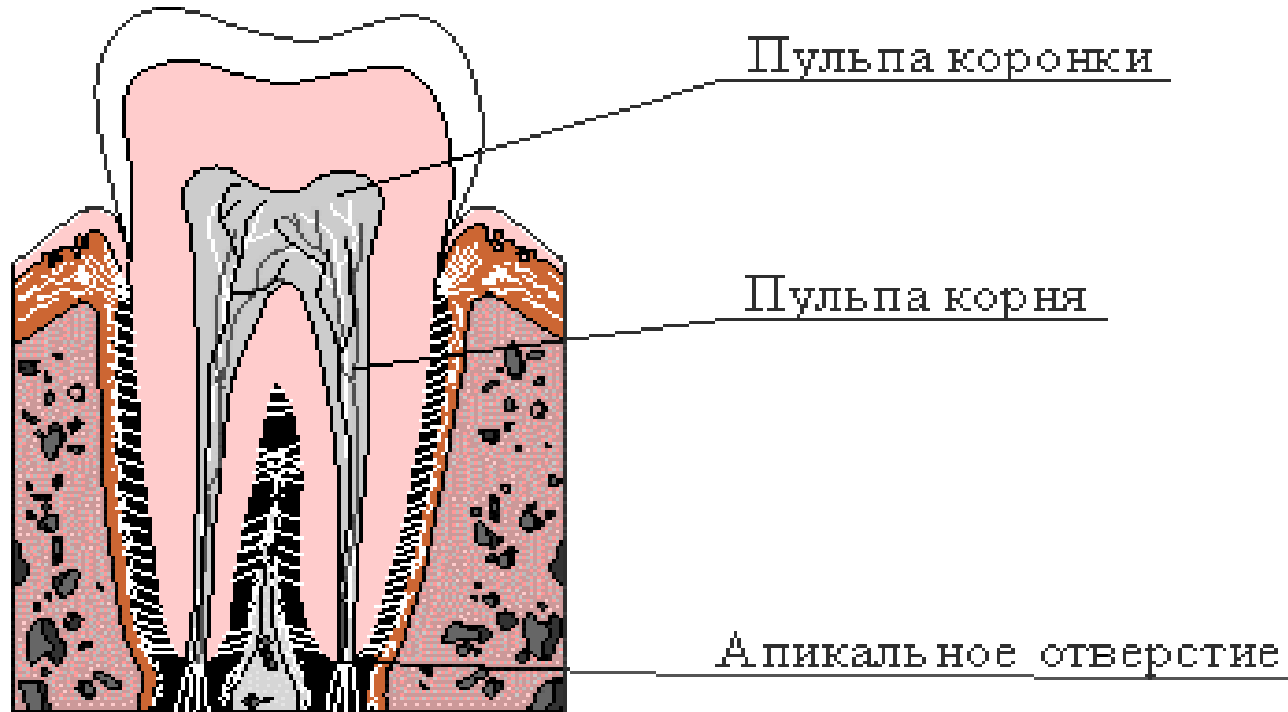
- The structure of the tooth - anatomy - isolated crown, neck and root.



- Crown - this is the part which is partially or completely protrudes above the gum after eruption. External hard dental crown is covered with enamel, comprising a compound florets. Under it is a dense substance similar to bone (dentin). The root is surrounded by a layer of special material - dental cement, by which it is attached to the jaw bone

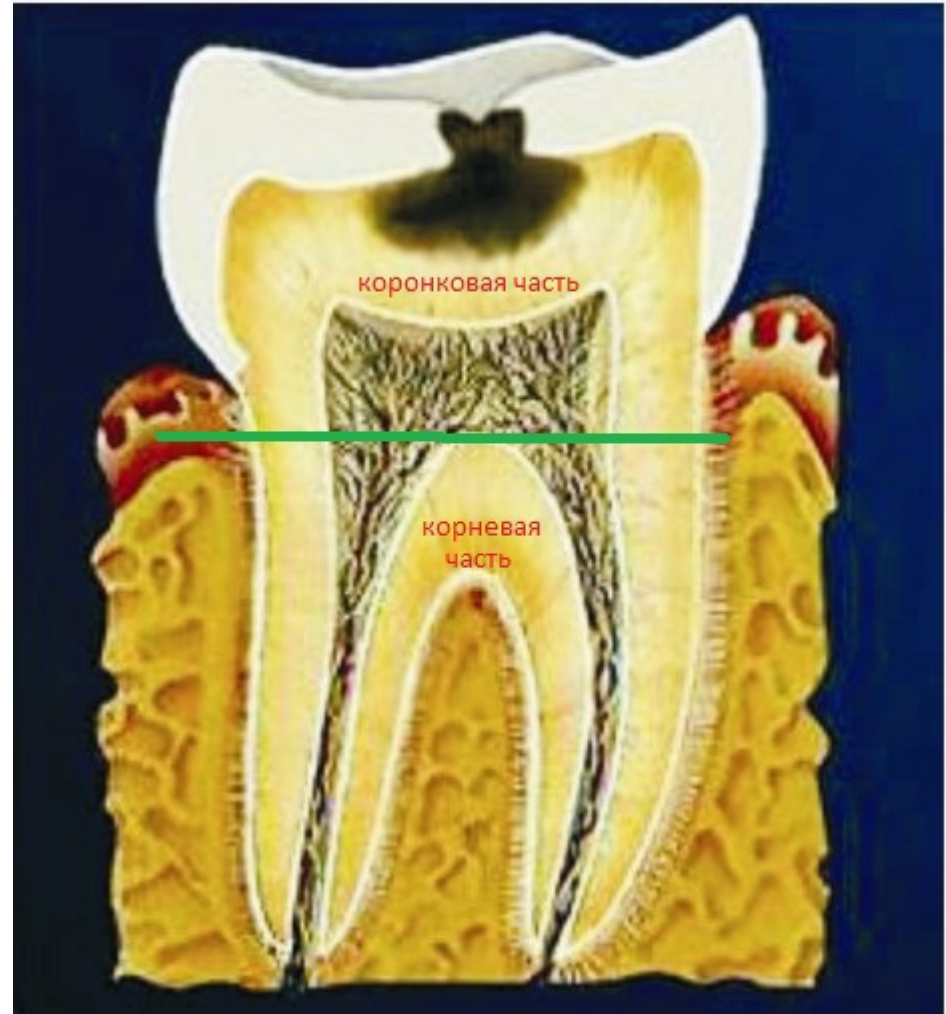


- inside the tooth cavity filled with pulp formed by loose connective tissue that contains blood vessels and sensory nerves.

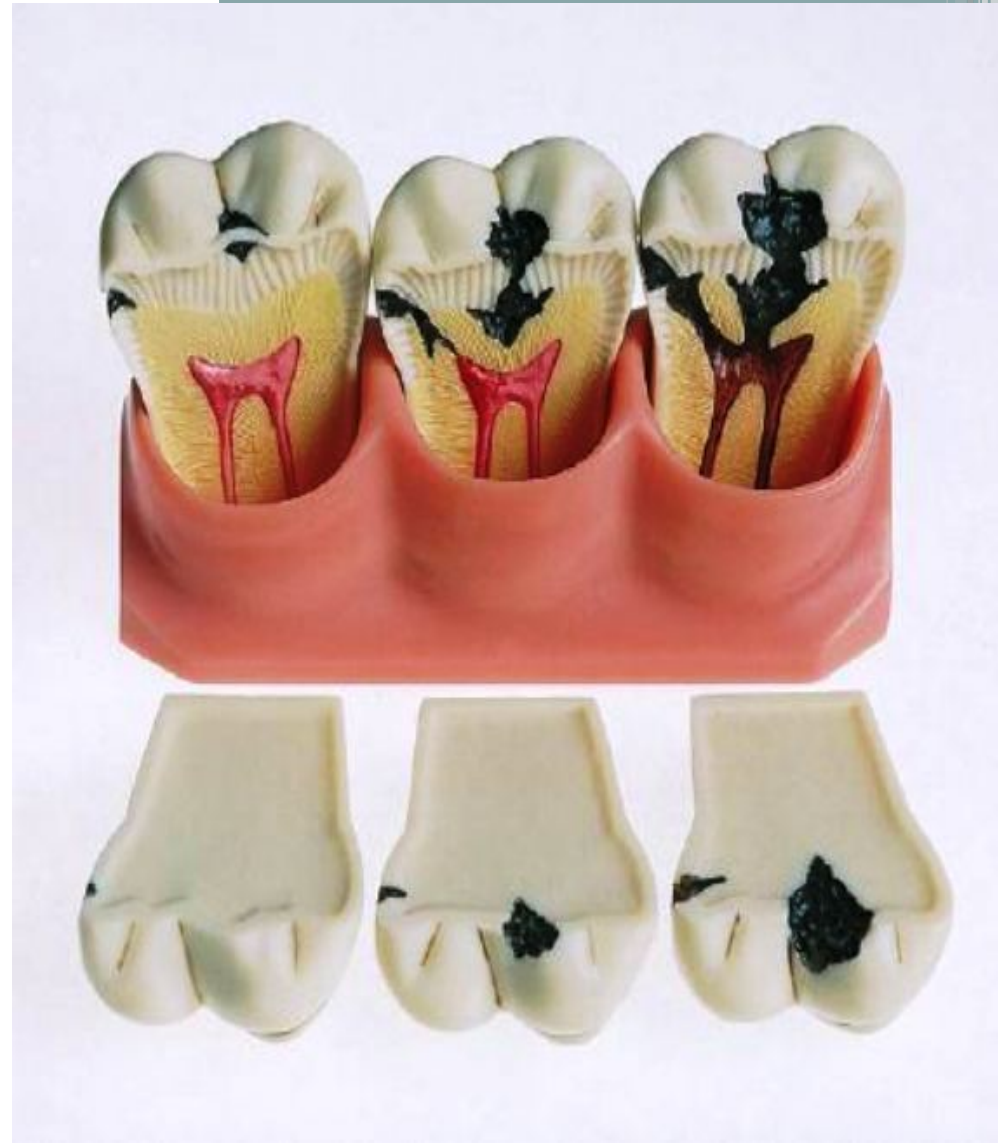

Caries

- Cavities - pathological process is the gradual destruction of bone tissue or teeth.

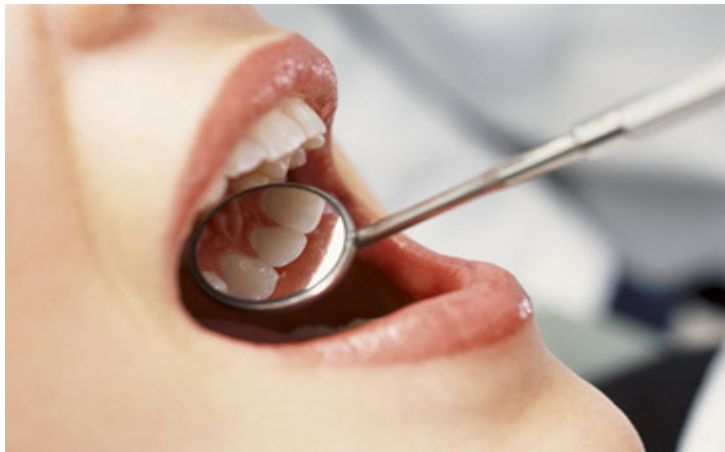

- Reason dental bone - dystrophic or infection in the bone , leading to necrosis of bone sections with subsequent absorption or rejection of dead mass and bone formation defect. Cavities can accompany some specific inflammatory processes (tuberculosis, syphilis)



Prophylaxis of diseases of cavity of mouth

- To visit stomatology 1-2 times per a year
- If there are diseases, a doctor must conduct sanitization of cavity of mouth
- To clean the teeth are 2 times per a day
- To utilize prophylactic paste

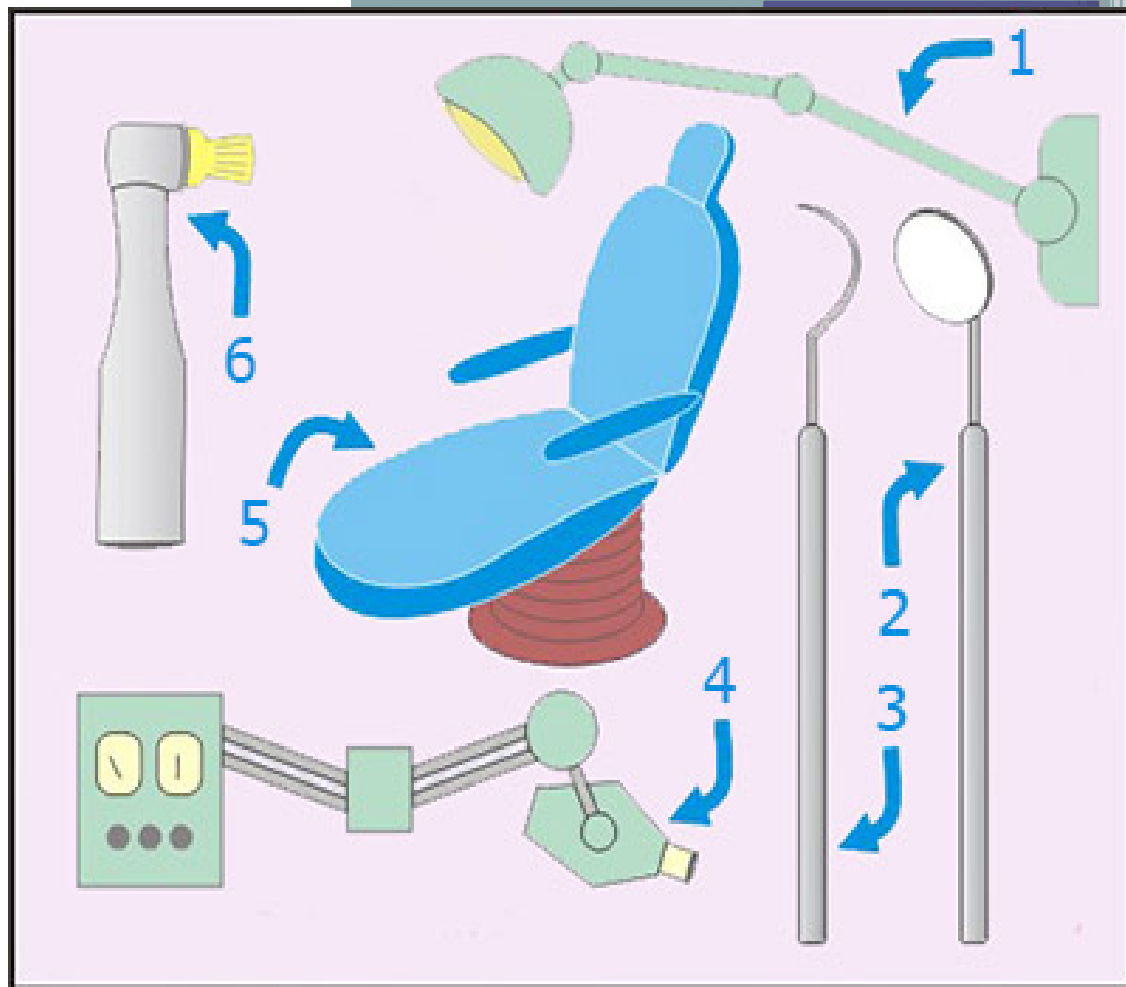


Instruments
utilized in stomatology

- Dental mirror
- Probe
- Dental foseps



1. Dental light –
стоматологический
светильник.
 2. Dental mirror –
стоматологическое
зеркало.
 3. Dental explorer –
стоматологический зонд.
 4. X-ray machine –
рентгеновский аппарат.
 5. Dental chair –
стоматологическое кресло.
 6. Tooth polisher –
полировальное
приспособление.
- приспособление.



- Скажите по-английски:
Верхняя челюсть; нижняя челюсть;
молочные зубы; известны как; костная
структура.
- Вставьте вместо точек нужный предлог:
The teeth are ... the upper and lower jaws. (on,
by)
... the time the child is two he has twenty
teeth. (at, by)
Man has two sets ... teeth only. (of, at).

- Переведите шутку:
Laughter is the best Medicine
Dentist: Have you seen any small boys
ring my bell and run away?
Policeman: They were not small boys –
they were grown-ups.
A: This is the second day your wife has
a toothache. Why don't you do
something about it?
B: But I do. I put cotton wool in my ears.



Sources:

- Мухина В.В. Английский язык для медицинских училищ. - М.: Высшая школа, 2002. - 141 с.
- Тылкина С.А. Пособие по английскому языку для медицинских училищ. - М.: АНМИ, 1997. – 157 с.
- Щедрина Т.П. Английский язык в медицине. - М.: Высшая школа, 2004. – 207 с.



Thank you!

